

Research Article

Sugar Mill Effluent Induced Histological Changes in Heart of *Channa punctatus*

Suman Prakash* and Ajay Kapoor

Department of Zoology, Agra College, Agra-282001, U.P., India.

Abstract: Sugar mill effluents are not so toxic like pesticides, but they contain many organic and inorganic reactive compounds which can affect the life of the organisms. These reactive compounds accumulate and retard physiological activities in human beings also. Histological biomarkers can be indicators of the effects on organisms of various anthropogenic pollutants on organisms and are a reflection of the overall health of the entire population of that ecosystem. The alterations in cells and tissues of fish are recurrently used biomarkers in many studies as such changes occur in all the invertebrates and vertebrates inhabiting aquatic basins. Histological biomarkers embody tissue lesions arising as a result of previous or current exposure of the organism to one or more toxins. In other words, it can be stated that these compounds act as a slow poison. Keeping these points in view, the effect of sugar mill effluent is observed on histology of heart of freshwater fish *Channa punctatus*.

Keywords: LC₅₀, Pyknosis, Heart histology, Toxic effects.

1. Introduction

Histological and histopathological studies are useful tool for assessing the injury at the cellular level, when the xenobiotics which are present in the vicinity reach to the target tissue, ultimately drastic changes in form of biochemical as well as histopathological alterations appeared in the organisms. Histopathological alterations are the first indicator of any toxicant assault if an organism is exposed to them through any route. Sugar mills are associated with effluent characterized by biological oxygen demand and suspended solids, the effluent is high in ammonium content. Histological analysis appears to be a very sensitive parameter and is crucial in determining cellular changes that may occur in target organs, such as the gills, liver and gonads. A histological investigation may, therefore, prove to be a cost-effective tool to determine the health of fish populations, hence reflecting the health of an entire aquatic ecosystem. Heart study indicates that normal fish heart has its axis in the median plane of the body, ventricle is surrounded by the lobes of liver. Toxicant stress produces great assault on the histological status of the heart, which has been investigated in the present study. The Chhata Sugar Mill (Mathura) has been taken as a case study for this study purpose to justify the pollutional standards. *Channa punctatus* (Bloch.) is an

easy handling fish, it is easily available and can be maintained in laboratory aquaria. It is highly sensitive to less amount of any toxicant or pollutant, thus it is selected as a model for the present study. Hence it is necessary to explore the toxic effects of Chhata sugar mill effluents on heart histology of fish *Channa punctatus* (Bloch.).

2. Material and Methods

2.1 Experimental Fish

The air-breathing teleost *Channa punctatus* (Bloch.) have been selected for the present investigation (Plate-1a & b). Fishes were collected from Government Fish Farm, Laramada village, Agra and other local freshwater resources. The experiments were done in the Research Laboratory of Zoology Department, Agra College, Agra.

2.2 Maintenance and Feeding of Experimental Fish

The experimental fishes *Channa punctatus* (Bloch.) were kept in clean large glass aquaria measuring 75cms X 37.5cms X 37.5cms. The water, used for keeping fishes, was stored before one week to remove unfavourable gases. Dechlorinated water was used throughout the experiment. Fishes were kept in aquaria at the temperature ranging from 30⁰C to 35⁰C.

The experimental fishes were acclimatized to the laboratory conditions for one week prior to experiment. The water of aquaria was changed every alternate day. The fishes were fed on readymade fish food. The food was given daily two times and feeding was disrupted 24 hours prior to the experiment.

2.3 Experimental Chemical

Sugar mill effluents collected from Chhata Sugar Mill, Mathura which contains various organic and inorganic effluents was used for the histochemical experiment.

2.4 LC₅₀ determination

In order to estimate the LC₅₀, the fishes of different experimental sets have been treated with different concentrations of Sugar mill effluent. Five concentrations 100ml/25L, 200ml/25L, 300ml/25L, 400ml/25L and 500ml/25L have been selected and for each concentration, the mortality number of fishes at different time intervals viz. 24 hrs, 48 hrs, 72 hrs and 96 hrs. On the basis of LC₅₀, sublethal concentration has been determined.

2.5 Tissue Collection

The control and experimental fish; *Channa punctatus* (Bloch.) were killed under light chloroform anesthesia. They were dissected carefully and the heart was taken out for histological examination accordingly.

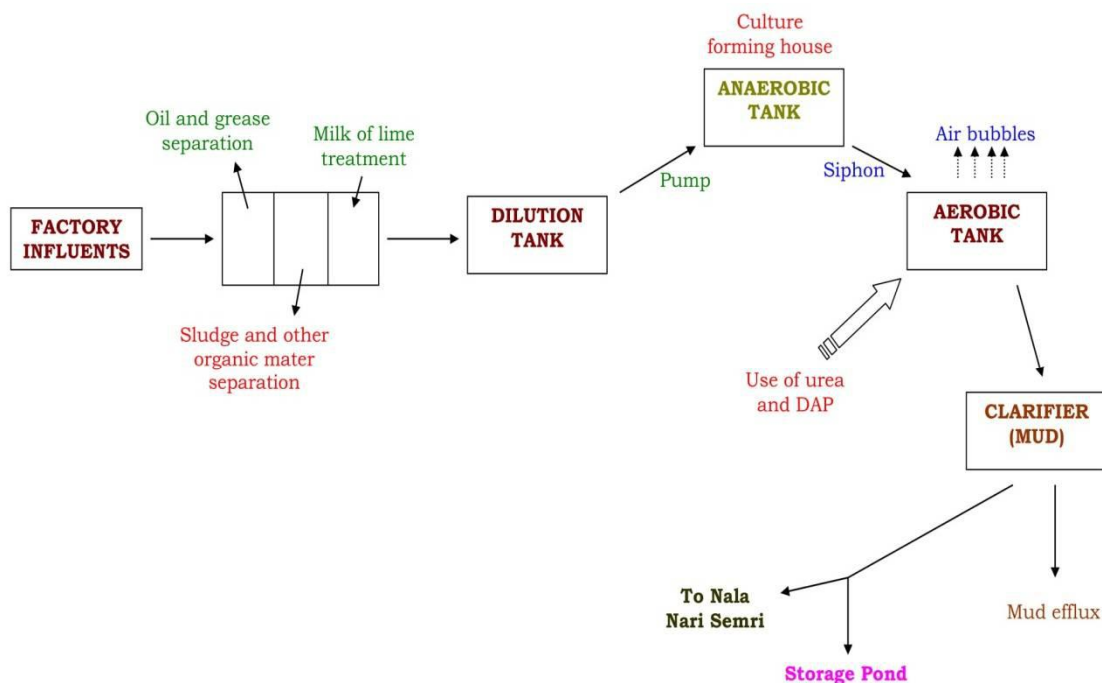
2.6 Histological Study

The collected tissue is fixed in the Bouin’s solution. After washing and dehydration, the tissues

were embedded in paraffin wax. The sections were cut at 5 microns and stained with haemotoxylin and eosin (Humason, 1979). Sections were examined under trinocular research microscope and photomicrographs were taken.

3. Results and Discussion

Heart of fish is venous heart as it contains only deoxygenated blood. It is two-chambered with an auricle and a ventricle. Heart is thick-walled, hollow, muscular pumping, and endocrine organ. Wall of heart has three layers endocardium is innermost which is lined by endothelium on a basal lamina. A subendothelial layer of collagenous and elastin fibres, fibroblasts and some smooth muscle cell layer with blood and lymphatic vessels, nerve fibres, and Purkinje fibres of the heart's conducting system is present (Plate-IIa). After 24 hrs treatment of sugar mill effluent, some sign of pyknosis occurs with 25.75ml/25L sugar mill effluent treatment (Plate-IIb). Splitting of muscles has been observed at 48 hrs stage of treatment with a dose of 25.75ml/25L sugar mill effluent (Plate-IIc). Pyknosis and degeneration is somewhere observed between normal muscles with 25.75ml/25L sugar mill effluent treatment after 72 hrs (Plate-IId); while pyknosis, degeneration and splitting of muscles is more prominent as compared to other stages after 96 hrs with 25.75ml/25L sugar mill effluent treatment (Plate-IIe) and degeneration and extensive splitting of muscles and highly pyknotic cells has been observed after 1 week treatment with sublethal dose of 25.75ml/25L sugar mill effluents (Plate-IIf).



EFFLUENT TREATMENT PLANT OF CHHATTA SUGAR MILL, MATHURA



Plate-1a: Dorsal view



Plate-1b: Ventral view

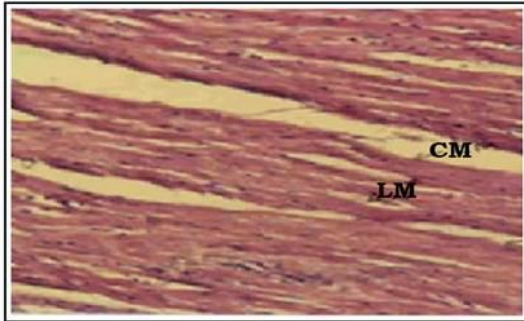


Plate-IIa
Control

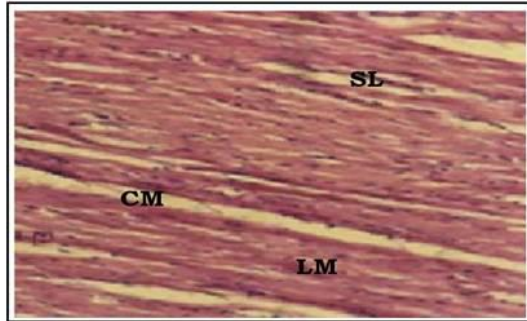


Plate-IIb
24 hrs



Plate-IIc
48 hrs




Plate-IId
72 hrs

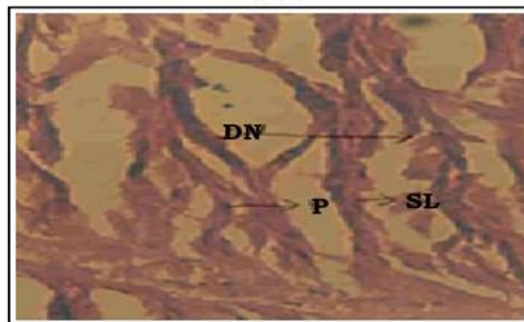


Plate-IIe
96 hrs

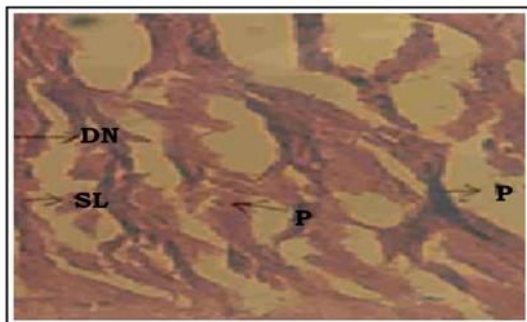


Plate-IIf
1 week

Plate-II: Histopathological Changes in Heart Sections.

LM - Longitudinal muscle; CM - Circular muscle; SL - Splitting of muscle; DN - Degeneration; P - Pyknosis.

A layer worth calling a subendocardium is not visible throughout the heart. Myocardium possess cardiac muscle fibres, bundled and wound in spiralling sheets, thicker in the ventricle while thin in the atria and blood vessels. Epicardium (visceral pericardium) is outermost layer. Heart valves are atrioventricular valve

and semilunar valves. Sinus venosus contains sinoatrial node of thin, modified, cardiac muscle fibres, a pacemaker influenced by parasympathetic and sympathetic autonomic nerve fibres regulating the rate of heartbeat. Atrial myocytes synthesize atrial natriuretic factor (ANF), which relaxes blood vessels

and increases the excretion of sodium and water by the kidney, it is thus a partial counterweight to the renin-angiotensin system. Control slide of heart shows longitudinal muscles in good condition. Histological studies were carried out in the heart of exposed *Channa punctatus* (Bloch.) from 24 hours to 1 week. Normal histology of fish heart has its axis in the median plane of the body. Its ventricle is nearly surrounded by the lobes of the liver. The heart is two-chambered. The pericardium is closely applied to the auricle and major vessel of the heart, but posteriorly around the ventricle, it is loosely placed. Pathological changes observed in different groups of fish heart varied. In control group (untreated group), the structure of heart was normal, showing normal arrangement of cardiac muscles and nuclei. Endocardium, myocardium and epicardium were normal. In treated groups (24 hrs, 48 hrs, 72 hrs, 96 hrs, 1 week), the fish heart showed some significant histological results which were more significant in the 1 week treatment of sugar mill effluent. These changes were splitting of muscles, dislocation of nuclei, muscular atrophy, pigment accumulation, destruction and loss of striation in cardiac muscles, splitting of longitudinal tissues and necrosis. Similar results were observed by Areechon and Plumb (1990) after malathion exposure to fish, Almeida *et al.*, (2001) in freshwater fish after cadmium effects and Zhang *et al.*, (2005) in goldfish after heavy metal treatment.

Changes in the pericardium, as well as the myocardium, were spectacular, with severe myocardial changes characterized by fragmentation of myofibrils and cellular infiltrations in the present study, which is in accordance with the findings of Arellano *et al.*, (1999), Desai *et al.*, (2004). After passing through the blood vascular system the toxic substance could have targeted the cardiac tissue, causing extensive damage. In the present investigation, fish, *Channa punctatus* (Bloch.) used as animal model because fishes are the most sensitive indicator against any physical and chemical change in the aquatic environment. For histological and histopathological investigation of fish heart has been taken in the present study to observe the fluctuations at the cellular level caused by the sugar mill effluents.

4. Conclusion

Sugar mill effluents are quite harmful to humans and other organisms. They contain many organic and inorganic materials, solid waste and hazardous compounds which cause several abnormalities at histological level in exposed individuals. To control these problems sugar mills should try to minimize the pollutant concentration by constantly repairing and maintaining discharge plant. Use of some compounds like milk of lime is very important in regulating optimum effluent discharge. Generally, anaerobic processes are preferred to decompose sludge because

they release oxygen to atmosphere and decompose a huge amount without any requirement. At Chhata Sugar Mill, although all the pollution control measures are used, but they are rather obsolete, they are successful to some extent, but pollution threat to local population is always there. It is suggested that the mill should take some control measures using advanced disposal instruments of international standards to minimize and convert the waste material in less harmful form to conserve the surrounding ecology.

References

- [1]. Allinson, G., Nishikawa, M., De Silva, S.S., Laurenson, L.J. & De Silva, K. (2002). Observations on metal concentrations in tilapia (*Oreochromis mossambicus*) in reservoirs of south Sri Lanka. *Ecotoxicol. Environ. Saf.*, **51**(3): 197-202.
- [2]. Almeida, J.A., Novelli, E.L., Dal Pai Silva, M. & Júnior, R.A. (2001). Environmental cadmium exposure and metabolic responses of the Nile tilapia, *Oreochromis niloticus*. *Environ. Pollut.*, **114**(2): 169-175.
- [3]. Areechon, N. & Plumb, J.A. (1990). Sublethal effects of malathion on channel catfish, *Ictalurus punctatus*. *Bull. Environ. Contam. Toxicol.*, **44**(3): 435-442.
- [4]. Arellano, J.M., Storch, V. & Sarasquete, C. (1999). Histological changes and copper accumulation in liver and gills of the Senegales sole, *Solea senegalensis*. *Ecotoxicol. Environ. Saf.*, **44**(1): 62-72.
- [5]. Desai, A.K., Joshi, U.M. & Ambadkar, P.M. (1984). Histological observations on the liver of *Tilapia mossambica* after exposure to monocrotophos, an organophosphorus insecticide. *Toxicol. Lett.*, **21**(3): 325-331.
- [6]. Finney, D.J. (1971). *Probit Analysis*, Cambridge University Press, 303 pp.
- [7]. Förlin, L., Andersson, T., Balk, L. & Larsson, A. (1995). Biochemical and physiological effects in fish exposed to bleached kraft mill effluents. *Ecotoxicol. Environ. Saf.*, **30**(2): 164-170.
- [8]. Humason, G.L. (1979). *Animal Tissue Techniques*. 4th edition. W.H. Freeman and Company, San Francisco. 661 pp.
- [9]. Thophon, S., Kruatrachue, M., Upatham, E.S., Pokethitiyook, P. Sahaphong, S. & Jaritkhuon, S. (2003). Histopathological alterations of white seabass, *Lates calcarifer*, in acute and subchronic cadmium exposure. *Environ. Pollut.*, **121**(3): 307-320.
- [10]. Zhang, Y.M., Huang, D.J., Wang, Y.Q., Liu, J.H., Yu, R.L. & Long, J. (2005). Heavy metal accumulation and tissue damage in goldfish, *Carassius auratus*. *Bull. Environ. Contam. Toxicol.*, **75**(6): 1191-1199.